

# **MINIMALLY INVASIVE LUMBAR SPINE SURGERY**

# **Minimally Invasive Lumbar Spine Surgery**

**What is MISS ?**

# Minimally Invasive Lumbar Spine Surgery

- ✓ Minimize tissue trauma and blood loss
  - ✓ Minimize post-operative pain
  - ✓ Minimize hospital stay
  - ✓ Minimize recovery
- 
- ✓ But not at the expense of surgical success or morbidity

# Keys to Minimally Invasive Spine Surgery

- ✓ Smaller incisions
- ✓ Muscle splitting instead of muscle cutting
- ✓ Fluoroscopic and image-guided navigation

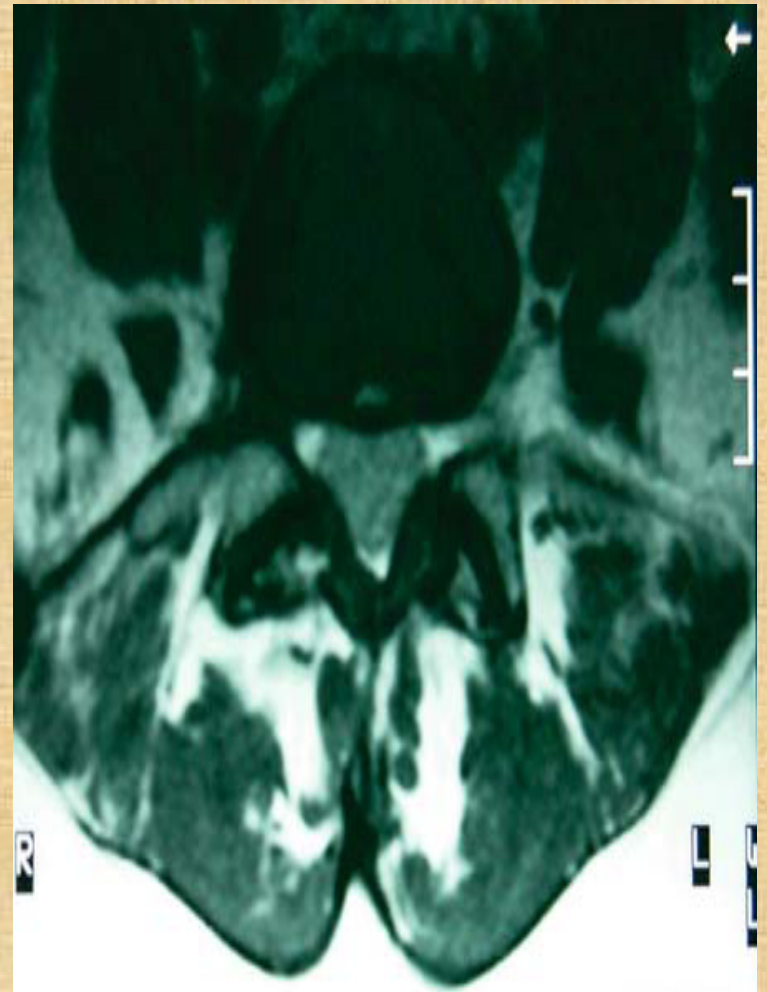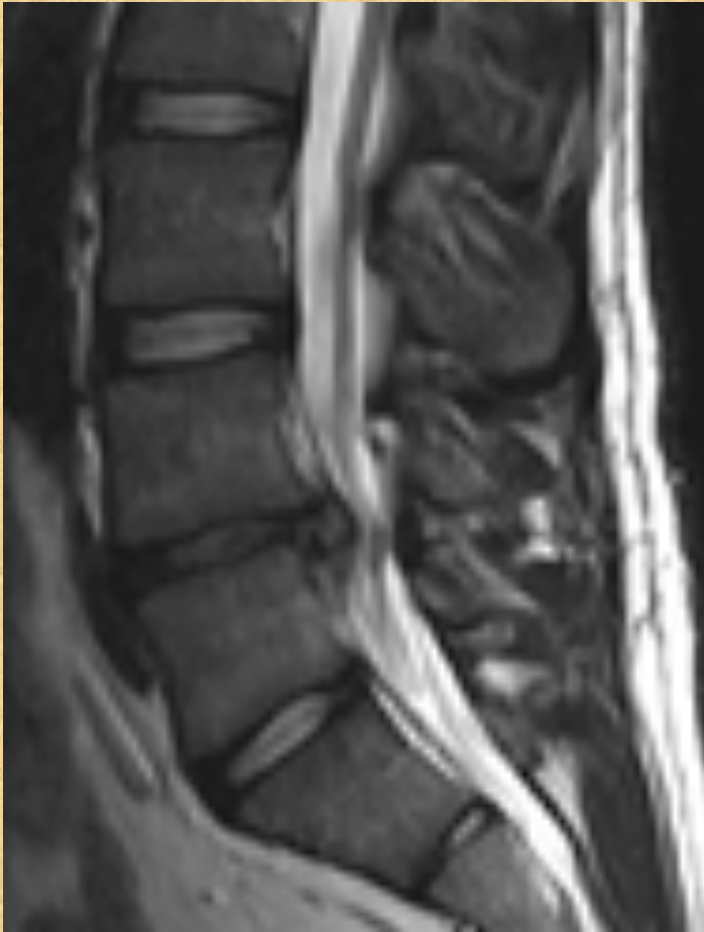
# Minimally Invasive Lumbar Spine Surgery

Lumbar  
Discectomy

Instrumentation

AIIMS Ex.

# Clinical Example. 1



# Percutaneous Lumbar Discectomy

- 1975 Hijikata

## Indications

- ✓ Failure to respond to non operative measures
- ✓ Correlative pain distribution
- ✓ Positive tension signs
- ✓ Correlative radiological studies
- ✓ With or without neurological deficits

## Contraindication

- ✓ Cauda Equina Syndrome

Hijikata S, Yamagishi M, Nakayama T, Oomori K:  
*Percutaneous discectomy: A new treatment method for lumbar disc herniation. J TodenHosp 39:5–13, 1975.*

# Percutaneous Lumbar Discectomy

- ✓ Small caliber cannula
- ✓ Dorsolateral insertion
- ✓ Positioned in the SAFE zone
- ✓ Quick look at the canal content
- ✓ Annulotomy
- ✓ Disc extraction



# Percutaneous Lumbar Discectomy

## Results

- Davis 1991 , 518 pt
- Success rate – 87%

## Conclusion

- Can be done for single level discs
- Role remains investigational and needs RCT validation of outcomes

Davis GW, Onik G, Helms C: *Automated percutaneous discectomy*. **Spine** 16:359–363, 1991

# Arthroscopic Discectomy

- 2.7-mm glass arthroscope combined with a video discoscope with a single working portal
- Arthroscopic disc surgery allows removal of herniated discs via a posterolateral approach
- Allow inspection of the annulus, spinal nerve, and foramina
- Kambin , reported an 87% successful outcome rate with arthroscopic microdiscectomy

# PERCUTANEOUS LASER DISCECTOMY

- **Ascher and Heppner** , in Germany, used carbon dioxide and neodymium lasers in neurosurgery
- Combined results of Ascher, Choy et al. , and others demonstrated 70 to 80% rates of long-lasting pain relief for more than 1000 patients
- **Lasers used :**
  1. Carbon dioxide
  2. Nd - YAG Laser
  3. Potassium-tytinal-phosphate (KTP) laser
- Choy et al 333 patients, with a mean follow-up period of 26 months, reported a **78.4%** success rate
- No controlled prospective studies have been performed

Choy DS, Ascher PW et al: *Percutaneous laser disc decompression: A new therapeutic modality. Spine 17:949–956, 1992.*

# PERCUTANEOUS INTRADISCAL RADIOFREQUENCY THERMOCOAGULATION

- Vaporization of the nucleus pulposus
- Lesions are produced at probe temperatures of 60 to 80°C.
- Two different mechanisms i.e. thermal coagulation of nociceptors and contraction of collagen Type I fibres, increasing the stability of the disc
- **Results:** 60% of the selected patients experienced profound reduction in pain

# Percutaneous Lumbar Discectomy

## Advantages

- ✓ Nerve roots and thecal sac not retracted
- ✓ Peri/epidural scar formation minimal
- ✓ Supportive myeloligamentous structures are not disturbed
- ✓ Post –op stay/cost/morbidity minimized.

## Disadvantages

- ✓ Learning curve
- ✓ Unable to address migrated disc fragments
- ✓ Unable to address bony or ligamentous pathology

# LUMBAR MICROENDOSCOPIC DISCECTOMY

- **Sofamor Danek** developed the instruments and technology.
- Combines standard lumbar microsurgical techniques with endoscopy
- A significant difference in mean operative blood losses
- There was a significant difference in the mean number of days of hospital stay
- Significant decrease in analgesic use

Muramatsu K, Hachiya Y, Morita C: *Postoperative magnetic resonance imaging of lumbar disc herniation: Comparison of microendoscopic discectomy and Love's method.* **Spine 26:1599–1605, 2001.**

- The MED system is an endoscopic system that enables posterior lumbar discectomy through a tubular retractor, with endoscopic observation
- Guide wire is inserted with the tip being fluoroscopically directed to the operative disc space.
- Dilators are sequentially inserted at the junction of the lamina and the lateral mass.
- 16-mm tubular retractor is then inserted over the largest dilator and fixed to the flexible arm assembly on the table
- Endoscope is fixed inside the tubular retractor
- Bone removal is performed with a small Kerrison punch or a high-speed drill

# SPINAL ENDOSCOPY

- FDA-approved indications for the use of spinal endoscopy are as follows:
  - documentation of pathological feature
  - documentation of decompression of structures
  - direct nerve inspection
  - inspection of internal fixation and delivery of therapeutic agents



# LAPAROSCOPIC LUMBAR SURGERY

## LUMBAR SPINAL FUSION

In 1991, **Obenchain**, reported the first use of a laparoscopic approach to the lumbar spine, for a discectomy

**Mathews** et al, laparoscopic anterior lumbar fusion

- Dural injury and epidural scarring can be avoided
- Retroperitoneal approach to the lumbar spine was first described by **Iwahara** (45) in 1963
- **Indications**
  - spondylolisthesis
  - degenerative disc disease
  - internal disc derangements
  - instability and for reoperations
- Retroperitoneal, minimally invasive, endoscopic spine surgery has the advantages of not requiring carbon dioxide insufflation or entrance into the peritoneal cavity and avoids dissection near the large vessels and the hypogastric plexus

# MINIMALLY INVASIVE PERCUTANEOUS POSTERIOR LUMBAR INTERBODY FUSION

- *METRx instrumentation and operating room set-up showing:*
- *A. METRx endoscope with disposable clamp*
- *B. flexible arm retractor*
- *C. Steinman pin and dilators;*
- *D. skin level tubular retractors*
- *E. modular system consisting of monitor, video integrator, recorder, and video printer with cart*
- *F. operating room set-up for endoscopic lumbar discectomy using lateral fluoroscopy and two video monitor*
- *G. operating room set-up using microscopic visualization.*

# Sequential operative procedure for endoscopic discectomy.

- Schematic drawing demonstrates area to dock Steinman pin.
- Lateral fluoroscopic image shows K-wire docked on laminofacet junction.
- Illustration shows properly placed dilators.
- Photograph illustrates dilators in place and METRx tubular retractor locked in place
- Lateral fluoroscopic image shows METRx tube in appropriate position.
- Illustration demonstrates endoscopic drilling of lamina.
- Illustration demonstrates proper positioning of METRx-MD tubular retractor.

## Minimally invasive PLIF/Pedicle Screws

- ✓ Same final result as open procedure
- ✓ Much less destructive:
  - Shorter skin incision
  - Minimal muscle trauma
  - No significant soft tissue retraction
- ✓ Less pain
- ✓ Shorter post-operative hospital stay

# AIIMS Experience



- **Sarkari.A, Gupta.D, Mahapatra.A.K:** *Minimally Invasive Spine Surgery in Acute Dorso-Lumbar Trauma: An Experiences of 14 Cases, IJNT, Dec-2011*
- Prospective study
- February 2009 to February 2011
- Jai Prakash Narayan Apex Trauma Centre, AIIMS, New Delhi

# AIIMS Experience

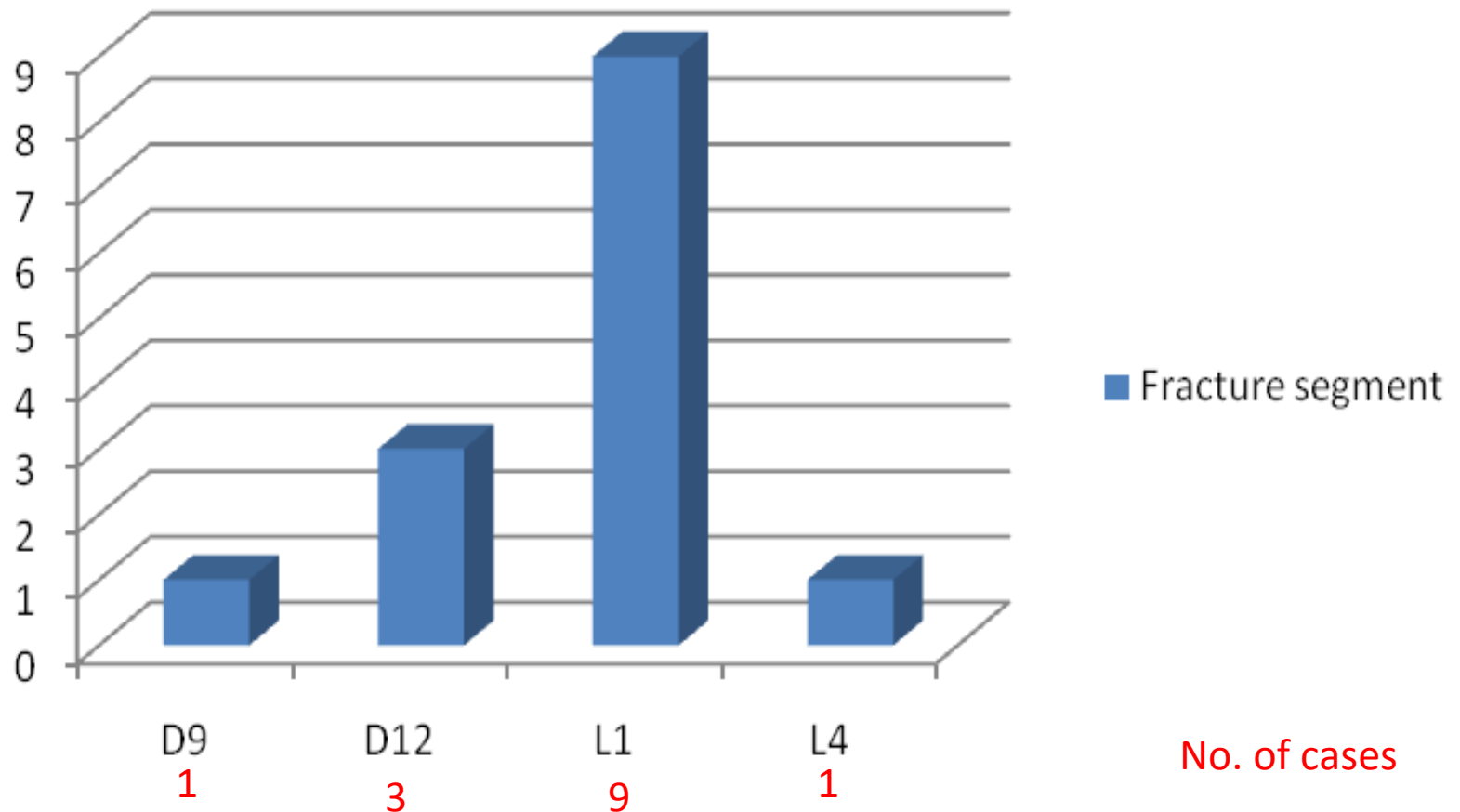


- 14 patients: 10 male 4 female
- Age: range 17-47 years (mean  $30.1 \pm 7.9$  yrs)
- Modified Frankel neurological performance scale (ASIA)
  - E = 2
  - D = 11
  - A = 1
- Mean TLCIS:  $5.2 \pm 0.6$
- Interval b/w injury and surgery: 1 – 18 days ( $5.5 \pm 4.3$  days).

# AIIMS Experience

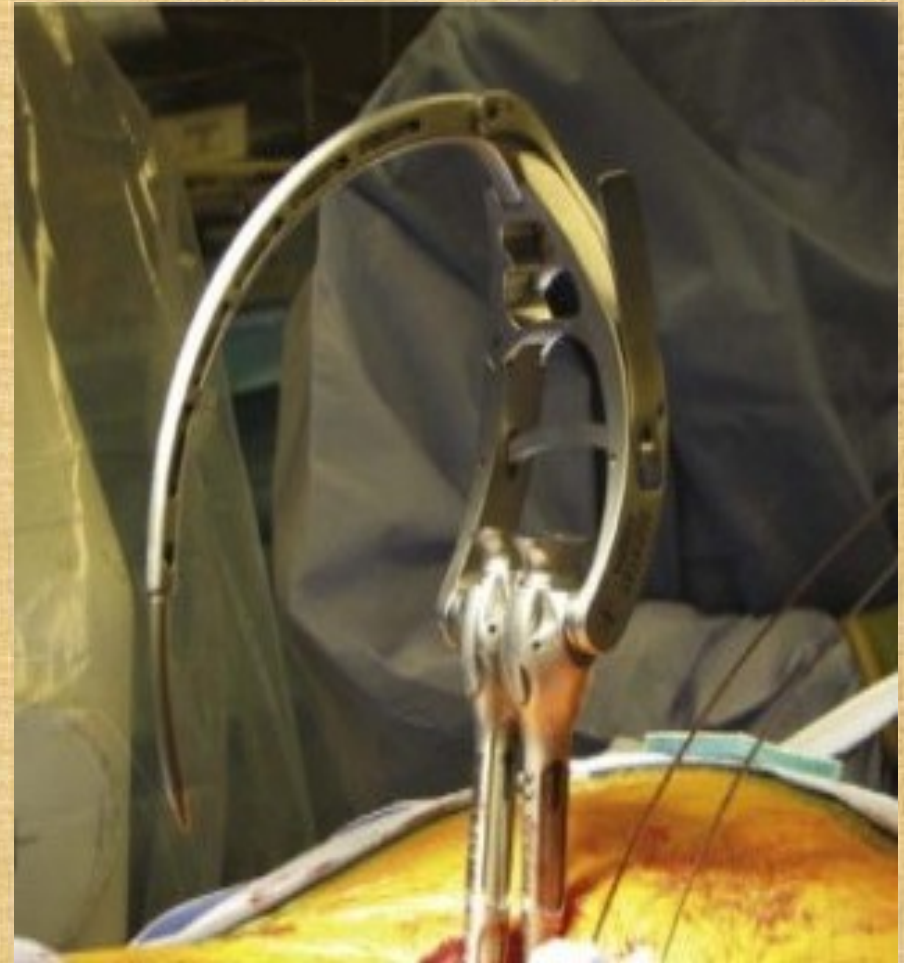

## Fracture segment



# AIIMS Experience

- ✓ C-arm fluoroscope: 12 cases
- ✓ 'O-arm' Computer assisted virtual fluoroscopic system : 2 cases
- ✓ Medtronic Sextant System was used for PSRF in all the patients

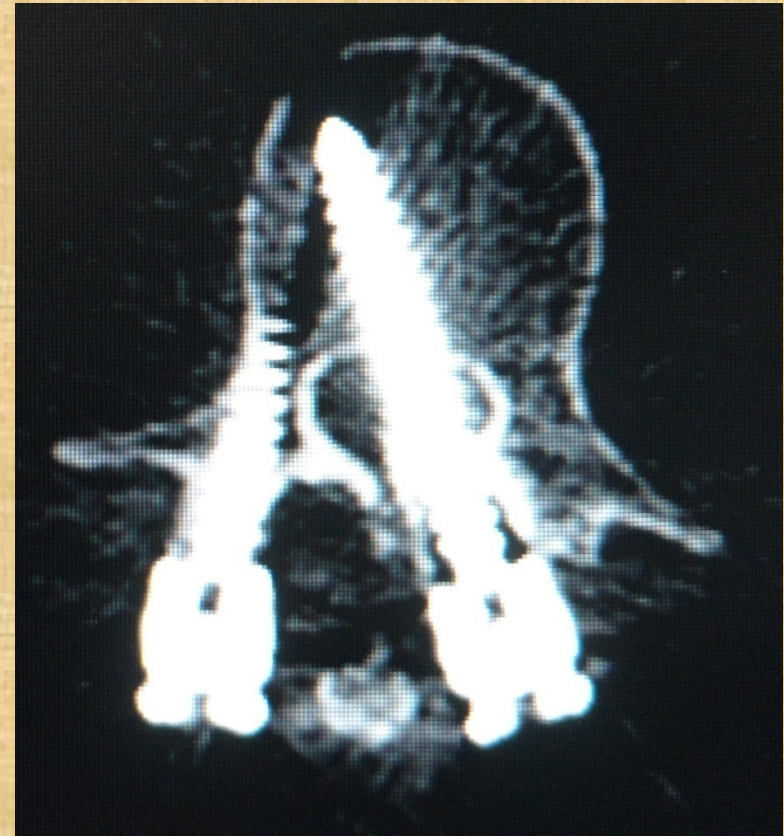



# AIIMS Experience : Results



- Complete procedure was successfully done percutaneously in 12 cases
- Total of 60 screws were put
- Blood loss ranged from **50 to 150 ml (mean  $94 \pm 16$  ml)**
- 2 patients needed conversion
- 2 (out of 60) screws misplaced





VARIABLE	PERCUTANEOUS	OPEN	P- Value
No. of cases (n)	14	207	-
Operating time (minutes)	95 ± 34	183 ± 57	0.0428 Significant
Blood loss (ml)	94 ± 16	458 ± 176	0.0078 Significant
Hospital stay (days)	3.8 ± 2.3	8.2 ± 3.9	0.0102 Significant
Screw malposition	3.3%	7.8%	0.0489 Significant
Infection rate	7.14 % (n=1)	6.73 % (n=14)	0.146 Not significant
Improvement in VAS at discharge	72.1 %	34.8 %	0.0167 Significant
Improvement in degree of kyphosis	72.8 %	78.8 %	0.06 Not significant

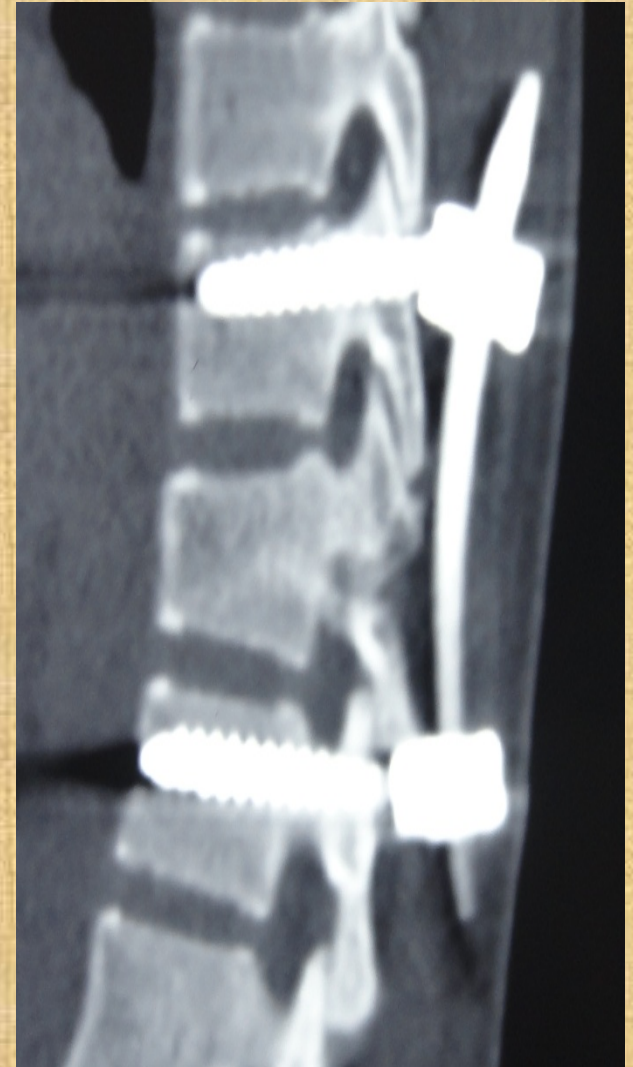


<b>STUDY</b>	<b>Foley et al (2001)</b>	<b>LEE et al (2004)</b>	<b>Schwender et al (2005)</b>	<b>Birrouneau et al (2011)</b>	<b>Present (2011)</b>
<b>N</b>	<b>12</b>	<b>17</b>	<b>47</b>	<b>24</b>	<b>14</b>
<b>Operating time (min)</b>	<b>90- 220</b>	<b>107.6</b>	<b>112.5</b>	<b>99</b>	<b>95</b>
<b>Blood loss (ml)</b>	<b>118</b>	<b>-</b>	<b>140</b>	<b>-</b>	<b>94</b>
<b>Post-op complications</b>	<b>8.3 % Op site hematoma</b>	<b>-</b>	<b>-</b>	<b>12 % Op site hematoma</b>	<b>7.14 % Infection</b>
<b>improvement in VAS %</b>	<b>-</b>	<b>70.8 %</b>	<b>-</b>	<b>75.3%</b>	<b>72.8%</b>
<b>Malpositioned Screws</b>	<b>2.1 %</b>	<b>4 %</b>	<b>-</b>	<b>1.8 %</b>	<b>3.3 %</b>
<b>Good to excellent outcome %</b>	<b>91.1 %</b>	<b>85 %</b>	<b>89.4 %</b>	<b>93 %</b>	<b>84.6 %</b>

# AIIMS Experience



- **Percutaneous pedicle fixation**
  - Safe and efficacious in the setting of acute polytrauma with spinal fracture requiring ligamentotaxis.
  - Reduces hospital stay (mean 3.8 days) and improves functional outcome in patients (mean VAS 2.2 post-op v/s 7.9 pre-op)
  - Useful in select cases
  - Steep learning curve involved.



**Thank You**